For skull and facial bones → have side markers inferior or inferior anterior for laterals.

SKULL

- Typically skull work is done PA
- Chin down moves petrous ridge up, chin up moves it down
- If patient can't move use CR angulation instead (caudal moves it down, cephalic moves it up)
- Remove earrings and any piercing in this area specifically
- Remove false teeth if possible
- Do it erect if possible, improved image quality
- Exposure is around 75kVp with a short time and standard SID
- Important to check for rotation or tilt
- Tilt is visible when IPL is not horizontal, rotation is when the MSP is aligned
- Hint → prevent rotation by placing fingertips on mastoid processes
- **ALWAYS WEAR GLOVES ON HEAD POSITONING PEOPLE ARE DIRTY AF**
- Be aware of asymmetry in peoples faces and using facial landmarks for positioning (DON'T USE NOSE AS MSP, OFTEN CROOKED)
- Everybody has a different head shape → changes where the petrous ridge is located
- Only include the skull vault (to the base of the skull/occipital bone)
- CT is mostly used for trauma, MRI for more pathologies/injury and particular structures
- US used for scanning neonatal brains, probes put through the fontanels
- Nuc med used for bony mets and pagets or brain tissue death
- CAN BE DONE ON SUSPENDED RESPIRATION TO IMPROVE STILLNESS
- Skull classifications: mesocephalic, brachycephalic and dolichocephalic
- Mesocephalic → the average skull shape, the skull width is between 75% and 80% of its length, the angle of the petrous ridge from the MSP is 47 degrees
- Brachycephalic → short and broad head, the width is 80% or greater than the length, angle is about 54 degrees
- Dolichocephaliac → long and narrow head shape, the width is less than 70% of the length, angle is about 40 degrees

Landmarks

- Top of the ear attachment (TEA) indicates the highest level of the petrous ridge
- Junctions of upper and lower eyelids are termed **canthi**, line between outer canthi of both eyes is the **interpupillary line**
- Supraorbital groove (above eyebrow) corresponds to the floor of the anterior fossa of cranial vault (the highest level of facial bone mass)

- Orbitomeatal line (OML) is located between the outer canthus and the EAM, often used when positioning OPG's. In aus we always use the OML
- The infraorbitomeatal line (IOML) is also called the anthropologic baseline, exists around 7 degrees below OML
- External auditory meatus
- Acanthion is the point where the top lip and nose meet
- Glabella
- Naison
- Mental point
- Frankfurts plane → inferior orbital margin to the top of the EAM

Anatomy
- **8 cranial bones**
- Sutures (coronal, sagittal, squamosal and lambodial)
- Calvarium (skull cap) → frontal, both parietal, occipital (4 bones)
- Skull floor → both temporal, sphenoid, ethmoid (4 bones)
- **14 facial bones**
- Frontal bone: glabella, superior orbital groove and margin, nasion, frontal tuberosity, orbital plates
- Orbital plates separate skull from facial bones, important in the tilt of lateral images
- Sphenoid is the only skull bone that articulate with all other skull bones
- In this order: anterior clinoids, sella turcica, posterior clinoids, dorsum sellae and then the clivus
- Important to understand petrous part of the temporal bone for positioning
- Must understand the sphenoid bone, important for lateral critique (whether or not wings superimpose)
- Ethmoid bone has cristal galli, perpendicular plate and cribiform plate

Clinical Indications
- Trauma
- Fracture
- Foreign bodies (particularly children sticking things up noses)
- **Multiple myeloma** (done with skeletal survey, mottled appearance)
- **Paget's disease**
- Shunt position (tube in lateral ventricle to drain excess CSF)
- Congenital malformation in children
- Plagiocephaly → when the sutures fuse together in a baby's skull before the brain is done growing, causing a weird head shape. **Craniostenosis** is the term for these joint fusing prematurely.

Towne's AP (ditched in trauma situations)
- Fronto-Occipital image with 30 degree caudal
- Shows the occipital bone, petrous ridges, foramen magnum with dorsum sellae imposed
- OML is perpendic to IR (TUCK CHIN DOWN)
- MSP is perpendic to IR

- 30 degree caudal angulation
- Centre 5 to 6cm above glabella
- IR in a portrait position if using CR
- Don't open collimation to whole face

Analysis Criteria

- Lateral borders of foramen magnum should be equidistance from lateral borders of the skull
- No tilt evident by petrous ridges at the same level
- Correct head position and CR shown by dorsum sellae and clinoid processes seen in foramen magnum

Caldwell's PA

- Occipital-Frontal image with 15 degrees caudal
- Shows the frontal, parietal and temporal bones, as well as frontal sinuses and superior orbital fissure
- OML and MSP perpendic to IR (TUCK CHIN DOWN)
- CR 15 degrees caudal
- With the centre point to exit at the nasion or a little higher

Analysis Criteria

- Lateral borders of the orbit equidistant to skull
- Petrous ridges horizontal and projected into lower third or orbit

Lateral Skull

- Shows cranial sides superimposed, orbital roofs, sphenoid sinus and seel turcica
- Side of interest closest to IR
- MSP parallel and IPL perpendic to IR
- IOML perpendic to front edge of IR
- Centre to 5cm **superior** to the EAM with receptor landscape
- Same positioning for all lateral images (sinus, facial bones etc)

Analysis Criteria

- Greater wings of sphenoid should be superimposed
- No tilt shown by orbital roof
- No rotation shown by sphenoid greater wings superimposed superior and inferiorly
- Sella turcica in profile with clinoids imposed

Additional Projections

- PA skull: positioning as for caldwells but with no CR angle, petrous ridge projected to level of superior orbital margins
- In trauma patient remains supine maybe with a cervical collar, clear the lateral c spine first
- Usually a lateral skull is only performed in trauma
- Elevate the with a sponge (if c spine cleared) and place IR next to patient to make sure back of head isn't coned off
- CR is horizontal and CP 5cm superior to the EAM, same position as normal lateral

- Trauma AP: OML perpendicular if not possible or angle CR, CP at naison

TOWNE'S (AP)

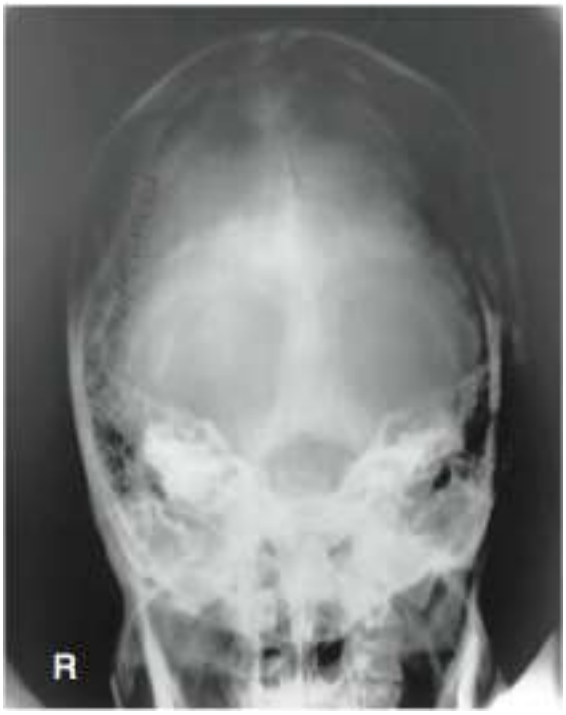

Method:
Patient with back against the bucky, depress chin so orbitomeatal line is perpendicular. Angle 30 degrees down. Centre to a point 5cm above the glabella, approx at the hairline. IR portrait position, include from base of skull to vertex in collimation.

Analysis:
Petrous ridges symmetric with borders of foramen magnum equidistant to skull edges **for no rotation**.

Dorsum sellae and clinoid processes should be seen in foramen magnum **for correct angulation**. Projected superiorly is under angulation, inferiorly is over angulation.

CALDWELL'S (PA)

Method:
Face the bucky, depress chin so OML is perpendicular to the IR. Angle 15 degrees caudal. CP to exit at naison.

Analysis:
Lateral borders or the skull should be equidistant **to indicate no rotation**.

Petrous ridges should be horizontal **to show no tilt**.

Ridges projected in the bottom third of orbits **to show correct angulation**.